

CLINICAL REPORT

Dynamic Abutment: A method of redirecting screw access for implant-supported restorations: Technical details and a clinical report

Eva Berroeta, DDS, Ms,^a Ion Zabalegui, MD, DDS,^b Terrence Donovan, DDS,^c and Winston Chee, DDS^d

INTRODUCTION

Today's patients expect longevity, function, and esthetics from their implant-supported restorations. The esthetic outcome of an implant-supported restoration is dependent on the soft tissue contour¹ and affected by the appropriate positioning of the implant. However, the presenting anatomy of the anterior maxilla often does not allow for an implant angulation that will allow a screw-retained restoration without the use of additional components. Often the remedy for this type of implant angulation is to provide an abutment designed to receive a cemented restoration. Cemented restorations have disadvantages compared with screw-retained restorations, including the consequences of excess cement and lack of retrievability.^{2,3}

Several authors have advocated approaching ideal implant placement from a 3-dimensional perspective.^{4,5} They describe the most significant error in implant positioning as angling the implant too far facially, thereby apically displacing the soft tissue contours of the restoration.

The use of screw-retained or cemented preangled abutments is a prosthetic option. However, these components require implants to be placed more apically to accommodate the labial dimensions of preangled

ABSTRACT

The esthetic outcome of implant-supported restorations is affected by the implant position. A well-placed implant will allow appropriate contours of the restoration and together with an adequate volume of soft tissue will result in a functional and esthetic restoration. When a screw-retained restoration is anticipated, an implant that is angled too far facially would be esthetically unacceptable.

In 2004, an abutment called the Dynamic Abutment (Talladium International Implantology) became commercially available. This abutment can allow a deviation of the restoration screw access angle to the implant angle of up to 28 degrees while allowing a screw-retained restoration to be connected directly to the platform of the implant. The purpose of this article was to describe the components, technique, and clinical use of this abutment. (*J Prosthet Dent* 2015;■:■-■)

abutments whether they are for screw or cemented restorations. Also, timing these abutments with the nonrotating feature of the abutments and the cost of additional components can be issues (Fig. 1).

In 2004, a novel abutment design (Dynamic Abutment; Talladium International Implantology) was introduced that allows the angulation of the screw access to diverge from the angulation of the implant. This abutment makes it possible to alter the angulation of the abutment by up to 28 degrees, allowing for a screw-retained restoration with no additional component as opposed to an implant placed with an ideal angulation for screw retention. The angle correction occurs before casting the restorative framework.

In 2011, Cavallaro et al⁶ analyzed the results of photoelastic stress assessments,^{7,8} finite element analysis,⁹⁻¹¹ and strain-gauge¹² studies that indicated that increased abutment angulations result in a greater

^aVisiting Professor, Complutense University of Madrid, Spain.

^bVisiting Professor, Complutense University of Madrid, Spain.

^cProfessor and Section Head, Department of Operative Dentistry, University of North Carolina, Chapel Hill, NC.

^dDirector of Implant Dentistry, Co-director Advanced Education in Prosthodontics Program, Ostrow School of Dentistry of the University of Southern California, Los Angeles, Calif.

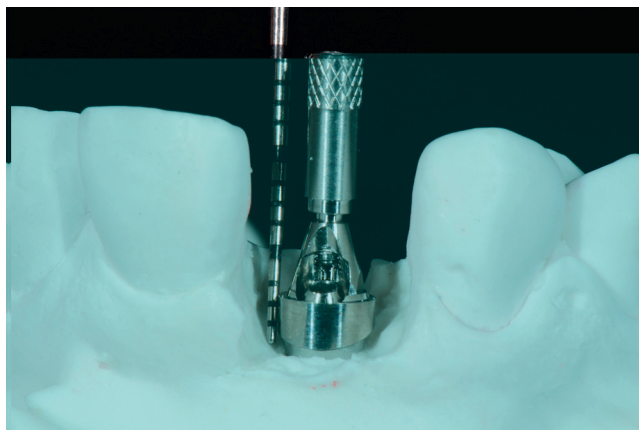


Figure 1. Preangled abutment. Note that screw access and exit is limited by antirotational feature of implant. Also note that labial collar is thicker than palatal collar requiring deeper implant placement to hide metal components.

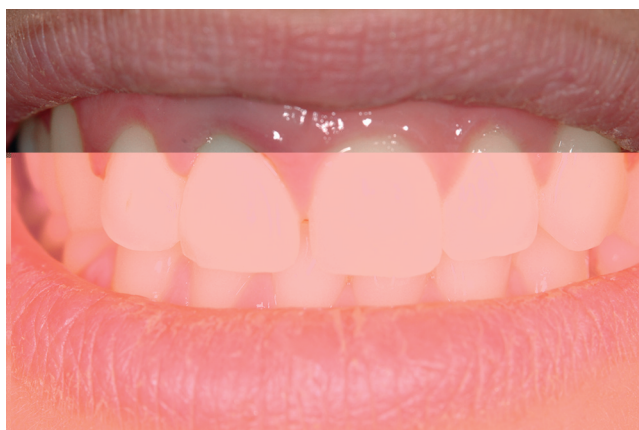

Figure 3. Preoperative photograph. Note high lip line and discoloration of fractured maxillary right central incisor.

amount of stress^{7,10,13} on prostheses and the surrounding bone than that associated with straight abutments. However, survival studies did not demonstrate a significant decrease in prosthesis longevity when angled abutments were used.^{13,14} Furthermore, there was no additional bone loss adjacent to implants that supported angled abutments¹⁵ compared with straight abutments, and angled abutments did not lead to an increased incidence of screw loosening.^{13,14,16}

The Dynamic Abutment consists of a base with a semisphere on which a burnout chimney sits and which can be freely moved to deviate from the axis by up to 28 degrees (Fig. 2). The fixation screw is unique and allows tightening while off axis with a screwdriver with a hexagonal 1.30-mm-faceted sphere.

This abutment is made to be compatible with the following implant systems: Straumann, Dentsply Astra Tech, Nobel Biocare (Brånemark system, Replace, Standard and Multiunit abutments), Biomet 3i, BTL, Phibo

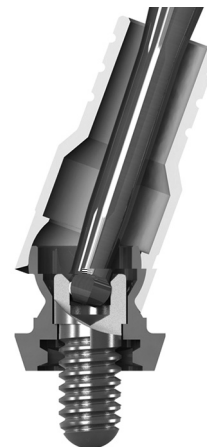


Figure 2. Dynamic abutment. Sectional view showing abutment and screw connection. Note screw and driver that allows alteration of access screw angulation from implant angulation.

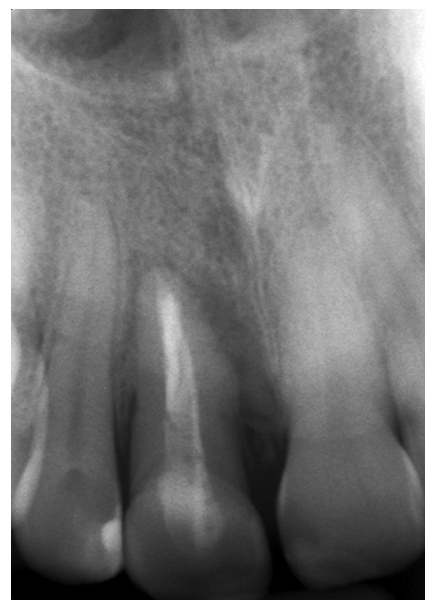

Figure 4. Preoperative radiograph showing fracture of right maxillary central incisor.

TSA, Eckerman, Zimmer, Klockner, DIO, and Ankylos implants.

CLINICAL REPORT

A healthy 35-year-old woman presented with a history of inflamed gingival tissue around a ceramic crown on her right maxillary central incisor that had been endodontically treated (Fig. 3). On clinical evaluation, the midfacial aspect of the tooth showed a 12-mm probing depth and a radiographic evaluation revealed a diagonal root fracture (Fig. 4).

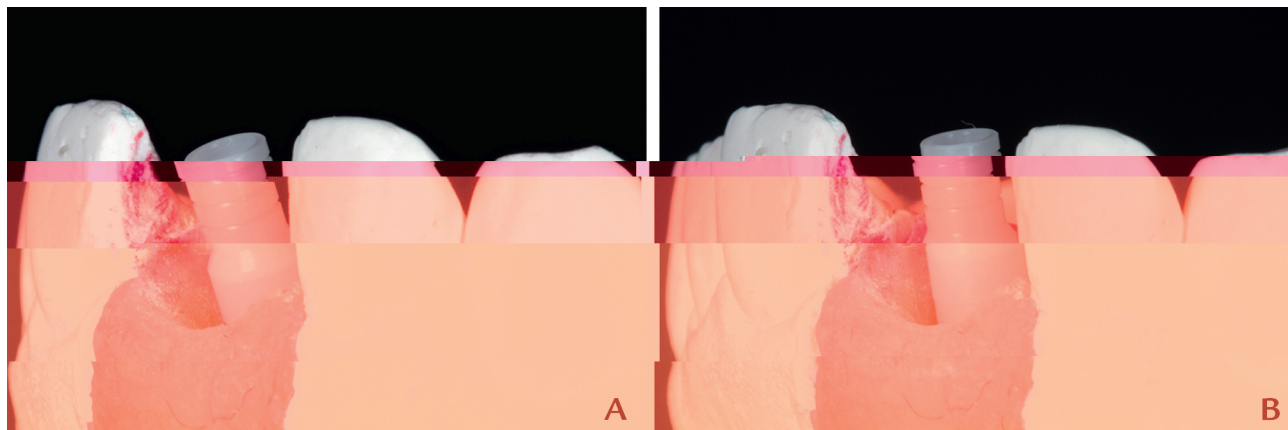


Figure 5. Dynamic abutment on cast. A, Without angle correction. B, With angle correction redirecting screw access to palatal surface.

The treatment plan included the extraction of this tooth, followed by an implant-supported restoration. She was referred to a periodontist who extracted the tooth together with the infected tissue and then placed an implant (Osseotite 4 mm platform 13 mm length; Biomet 3i). Good primary stability was obtained. Simultaneously, a connective tissue graft was placed with a tunnel technique to compensate for the resorption of the facial bone; this graft also served to seal the wound and conceal underlying implant restorative material.¹⁷ The radiograph revealed that the interproximal bone of the adjacent teeth was favorable to the maintenance of an interproximal papilla¹⁸ (Fig. 4).

A resin-bonded, partial fixed dental prosthesis with a metal framework and acrylic resin pontic was bonded to the adjacent teeth as an interim restoration during implant integration. Space was provided between the pontic and the edentulous ridge to facilitate connective tissue graft expansion.

In order to obtain an esthetic outcome, the implant restoration contour should transition from the dimensions of the implant platform to the correct cervical tooth anatomy; this is facilitated by using an interim restoration to form the periimplant mucosa.^{19,20} This was accomplished by making a preliminary impression of the implant poured with stone (Snow White; Kerr Corp). The stone around the implant was contoured to the appropriate cervical tooth anatomy, and a screw-retained interim restoration was created to fill the space.²¹ The resulting interim restoration was placed clinically and gradually displaced the soft tissues as directed by the shape of the submucosal contours of the interim restoration.

Su et al²² described the importance of soft tissue esthetics in relation to the emergence profile. This profile is largely determined by the soft tissues forming around the interim restoration. This submucosal contour can be provided to the dental technician so that it can be predictably replicated on the definitive restoration.

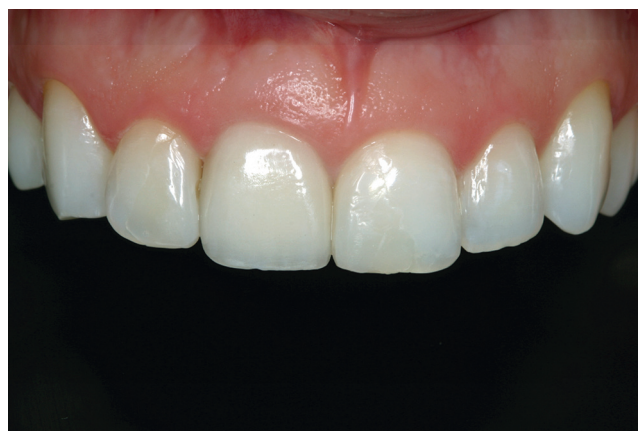

Figure 6. Postoperative view of restoration.

The definitive impression was made with polyether material (Impregum Penta H and L Garant Duosoft; 3M ESPE) and a custom tray and poured with Type IV stone (Fujirock; GC). The screw access as determined by the angulation of the implant was located at the incisal edge of the central incisor. This was altered with use of the Dynamic Abutment. Figure 5 shows the change of the angulation and how the screw access of the implant was redirected to the palatal surface of the restoration. The framework wax pattern was completed over the cylinder and was invested, burned out, and cast in a gold-palladium alloy (Esteticor Blancor; Cendres+Métaux). The porcelain (Creation; Willi Geller International) was then completed and delivered to the patient (Fig. 6).

DISCUSSION

Abutment angulation has been widely documented. Sethi et al¹³ reported on more than 2000 angled abutments with a survival rate of 98.6% over a 5-year period and 98.2% over a 14-year period.¹⁴ Eger et al²³ compared clinical parameters such as probing depths, gingival level, gingival index, and mobility between implants restored

with angled and standard abutments and found no significant difference for any of the parameters examined.

Ha et al¹⁶ compared the removal torque values (RTVs) of different abutments (straight, angled, and gold pre-machined direct) in external- and internal-hexagon implants after dynamic cyclic loading. They found that the angled abutment group showed significantly higher RTVs.

Early results from ongoing studies related to the Dynamic Abutment and investigating the ultimate fracture strength and RTV after cyclic loading at 5 different angulations at the Ostrow School of Dentistry of the University of Southern California indicate favorable retention of these abutments at different angulations.

SUMMARY

Implant-supported screw-retained restorations have the benefit of retrievability and do not have the liability of retained excess cement. When implants are placed within a 28-degree variance of the ideal trajectory, the Dynamic Abutment can be used and requires no increased depth of the implant or additional components.

REFERENCES

1. Grunder U. Crestal ridge width changes when placing implants at the time of tooth extraction with and without soft tissue augmentation after a healing period of 6 months: report of 24 consecutive cases. *Int J Periodontics Restorative Dent* 2011;31:9-17.
2. Agar JR, Cameron SM, Hughbanks JC, Parker MH. Cement removal from restorations luted to titanium abutments with simulated subgingival margins. *J Prosthet Dent* 1997;78:43-7.
3. Chee WWL, Duncan J, Afshar M, Moshaverinia A. Evaluation of the amount of excess cement around the margins of cement-retained dental implant restorations: the effect of the cement application method. *J Prosthet Dent* 2013;109:216-21.
4. Grunder U, Gracis S, Capelli M. Influence of the 3-D bone-to-implant relationship on esthetics. *Int J Periodontics Restorative Dent* 2005;25:113-9.
5. Tarnow DP, Cho SC, Wallace SS. The effect of inter-implant distance on the height of inter-implant bone crest. *J Periodontol* 2000;71:546-9.
6. Cavallaro J Jr, Greenstein G. Angled implant abutments: a practical application of available knowledge. *J Am Dent Assoc* 2011;142:150-8.
7. Clelland NL, Gilat A. The effect of abutment angulation on stress transfer for an implant. *J Prosthodont* 1992;1:24-8.
8. Clelland NL, Gilat A, McGlumphy EA, Brantley WA. A photoelastic and strain gauge analysis of angled abutments for an implant system. *Int J Oral Maxillofac Implants* 1993;8:541-8.
9. Kao HC, Gung YW, Chung TF, Hsu ML. The influence of abutment angulation on micromotion level for immediately loaded dental implants: a 3-D finite element analysis. *Int J Oral Maxillofac Implants* 2008;23:623-30.
10. Saba S. Occlusal stability in implant prosthodontics: clinical factors to consider before implant placement. *J Can Dent Assoc* 2001;67:522-6.
11. Lin CL, Wang JC, Ramp LC, Liu PR. Biomechanical response of implant systems placed in the maxillary posterior region under various conditions of angulation, bone density, and loading. *Int J Oral Maxillofac Implants* 2008;23:57-64.
12. Brosh T, Pilo R, Sudai D. The influence of abutment angulation on strains and stresses along the implant/bone interface: comparison between two experimental techniques. *J Prosthet Dent* 1998;79:328-34.
13. Sethi A, Kaus T, Sochor P. The use of angulated abutments in implant dentistry: five-year clinical results of an ongoing prospective study. *Int J Oral Maxillofac Implants* 2000;15:801-10.
14. Sethi A, Kaus T, Sochor P, Axmann-Krcmar D, Chanavaz M. Evolution of the concept of angulated abutments in implant dentistry: 14-year clinical data. *Implant Dent* 2002;11:41-51.
15. Celletti R, Pameijer CH, Bracchetti G, et al. Histologic evaluation of osseointegrated implants restored in nonaxial functional occlusion with preangled abutments. *Int J Periodontics Restorative Dent* 1995;15:562-73.
16. Ha CY, Lim YJ, Kim MJ, Choi JH. The influence of abutment angulation on screw loosening of implants in the anterior maxilla. *Int J Oral Maxillofac Implants* 2011;26:45-55.
17. Rungcharassaeng K, Kan JY, Yoshino S, Morimoto T, Zimmerman G. Immediate implant placement and provisionalization with and without a connective tissue graft: an analysis of facial gingival tissue thickness. *Int J Periodont Rest Dent* 2012;32:657-63.
18. Kan JY, Rungcharassaeng K, Umezaki K, Kois JC. Dimensions of peri-implant mucosa: an evaluation of maxillary anterior single implants in humans. *J Periodontol* 2003;74:557-62.
19. Chee WW. Provisional restorations in soft tissue management around dental implants. *Periodontol* 2000 2001;27:139-47.
20. Chee WW, Donovan T. Use of provisional restorations to enhance soft-tissue contours for implant restorations. *Compend Contin Educ Dent* 1998;19:481-6.
21. Bichacho N, Landsberg CJ. A modified surgical/prosthetic approach for an optimal single implant-supported crown. Part II. The cervical contouring concept. *Pract Periodontics Aesthet Dent* 1994;6:35-41.
22. Su H, Gonzalez O, Weisgold A, Lee E. Considerations of implant abutment and crown contour: critical contour and subcritical contour. *Int J Periodontics Restorative Dent* 2010;30:335-43.
23. Eger DE, Gunsolley JC, Feldman S. Comparison of angled and standard abutments and their effect on clinical outcomes: a preliminary report. *Int J Oral Maxillofac Implants* 2000;15:819-23.

Corresponding author:

Dr Eva Berroeta
Alameda Urquijo
10 Principal Derecha
Bilbao
SPAIN
Email: eva.berroeta@clinicaevberroeta.com

Copyright © 2015 by the Editorial Council for *The Journal of Prosthetic Dentistry*.